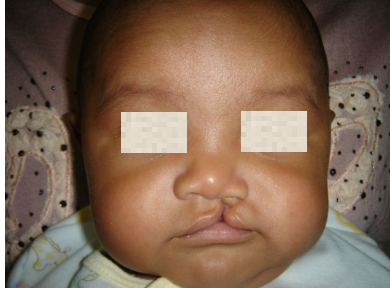

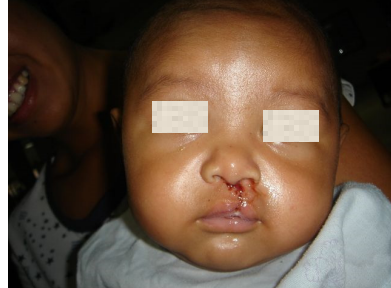Sample cleft cases with pre and post-operative photos

(August 2014 – July 2015)

Patient No.1



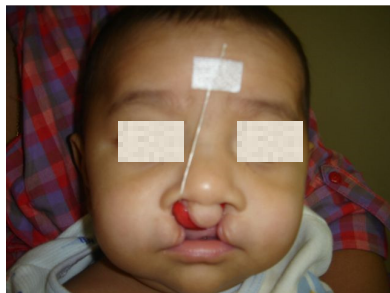Pre operative



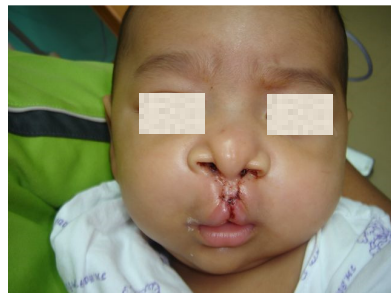Post operative

Name : C.C. **Gender :** Male **Age :** 3 months
DX : Unilateral, complete cleft lip and alveolar cleft left.
Associated anomalies : -
Name of Hospital : Songklanagarind Hospital
Date of the surgical treatment : 14/08/2014
Type of Operation : Primary Lip/Nose Unilateral Repair
Type of Repairs : Unilateral lip/Rotation-Advancement Variant.

Patient No.2



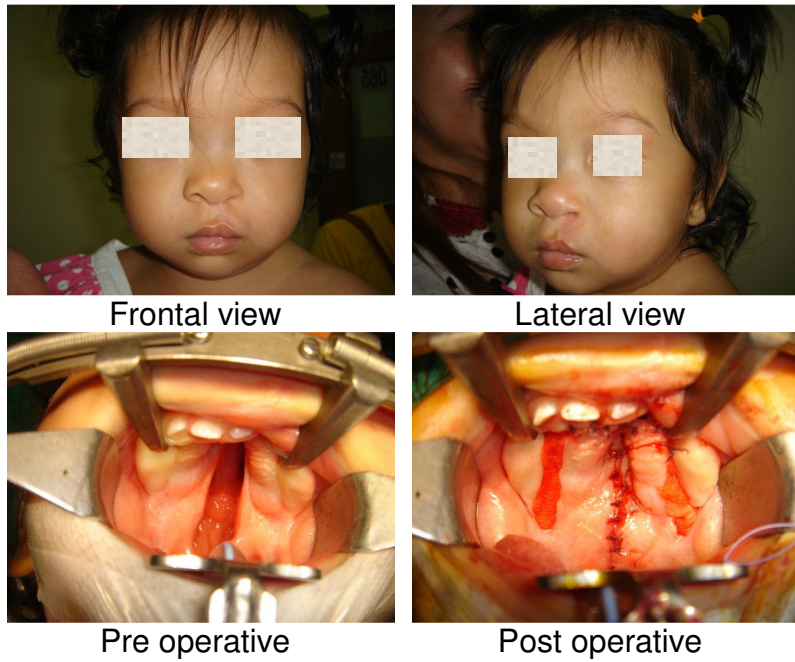
Pre operative



Post operative

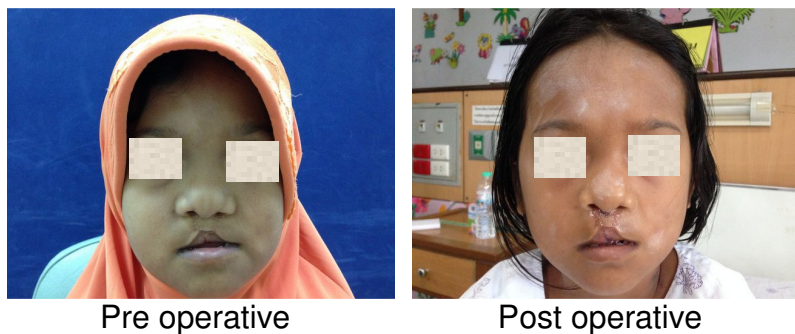
Name : M.B. **Gender :** Male **Age :** 4 months
DX : Bilateral, complete cleft lip and cleft palate.
Associated anomalies : -
Name of Hospital : Songklanagarind Hospital
Date of the surgical treatment : 26/02/2015
Type of Operation : Primary Lip/Nose Bilateral Repair
Type of Repairs : Bilateral lip/JB.Mulliken's Technique.

Patient No.3



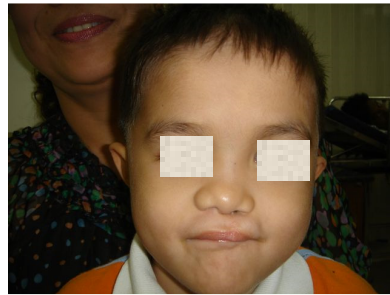Name : Y.P. **Gender :** Female **Age :** 11 months
DX : Unilateral, complete cleft lip and cleft palate left.
Associated anomalies : -
Name of Hospital : Songklanagarind Hospital
Date of the surgical treatment : 18/12/2014
Type of Operation : Primary Cleft Palate Repair.
Type of Repairs : Palate/Two Flaps palatoplasty and variants and IVVP.

Patient No.4

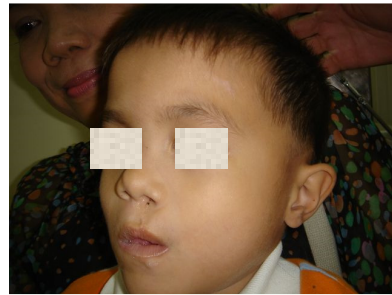

Name : S.S. **Gender :** Female **Age :** 8 years
DX : Bilateral, complete cleft lip and cleft palate.
Associated anomalies : -
Name of Hospital : Songklanagarind Hospital
Date of the surgical treatment : 11/06/2015
Type of Operation : Lip/Nose revision
Type of Repairs : Dibell interdigitation of triangular flap.

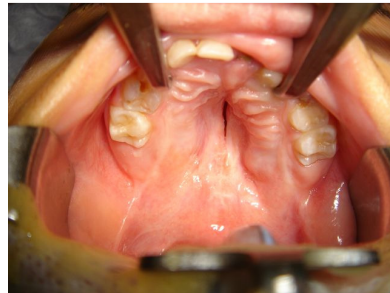Patient No.5



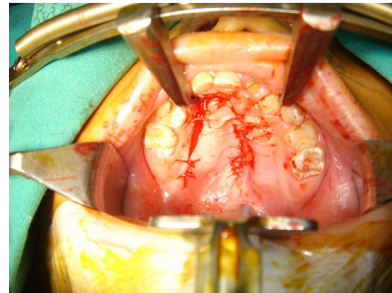
Frontal view



Lateral view



Pre operative



Post operative

Name : T.J. **Gender :** Male **Age :** 5 years
DX : Unilateral, complete cleft lip and cleft palate left.
Associated anomalies : -
Name of Hospital : Songklanagarind Hospital
Date of the surgical treatment : 25/06/2015
Type of Operation : Fistula Repair/Lip nose revision
Type of Repairs : Turnover flaps, mucoperiosteal flap with correction of nasal sill and excision excess vermillion.